

The effect of mode of breathing on craniofacial growth—revisited

Timo Peltomäki

Clinic for Orthodontics and Pediatric Dentistry, Center for Dental and Oral Medicine, University of Zurich, Switzerland

SUMMARY It has been maintained that because of large adenoids, nasal breathing is obstructed leading to mouth breathing and an ‘adenoid face’, characterized by an incompetent lip seal, a narrow upper dental arch, increased anterior face height, a steep mandibular plane angle, and a retrognathic mandible. This development has been explained as occurring by changes in head and tongue position and muscular balance. After adenoidectomy and change in head and tongue position, accelerated mandibular growth and closure of the mandibular plane angle have been reported. Children with obstructive sleep apnoea (OSA) have similar craniofacial characteristics as those with large adenoids and tonsils, and the first treatment of choice of OSA children is removal of adenoids and tonsils. It is probable that some children with an adenoid face would nowadays be diagnosed as having OSA. These children also have abnormal nocturnal growth hormone (GH) secretion and somatic growth impairment, which is normalized following adenotonsillectomy.

It is hypothesized that decreased mandibular growth in adenoid face children is due to abnormal secretion of GH and its mediators. After normalization of hormonal status, ramus growth is enhanced by more intensive endochondral bone formation in the condylar cartilage and/or by appositional bone growth in the lower border of the mandible. This would, in part, explain the noted acceleration in the growth of the mandible and alteration in its growth direction, following the change in the mode of breathing after adenotonsillectomy.

Adenoid face

The effect of mode of breathing on craniofacial growth has been a widely debated and controversial issue within orthodontics for decades. It has classically been maintained that because of large adenoids, nasal breathing is (partially) obstructed leading to mouth breathing and the stereotype of the adenoid face (Subtelny, 1954; Linder-Aronson, 1970), however, the complexity of this association has also been discussed (McNamara, 1981; Warren and Spalding, 1991; Trotman *et al.*, 1997; Vig, 1998). The adenoid face is characterized by an incompetent lip seal, a narrow upper dental arch, retroclined mandibular incisors, increased anterior face height, a steep mandibular plane angle, and retrognathic mandible compared with faces of healthy controls (Linder-Aronson, 1970). Comparable changes in the craniofacial structure have been described in a group of subjects with large tonsils (Behlfelt *et al.*, 1990). This development has been explained in a ‘mechanistic’ way as occurring by changes in the muscular balance. Because of mouth breathing, the tongue position in the oral cavity is low and the balance between forces from the cheeks and tongue is different compared with healthy children. This leads to a lower mandibular position and extended head posture with all the above-mentioned dental and skeletal consequences (Solow and Kreiborg, 1977; Linder-Aronson, 1979; Solow *et al.*, 1984; Figure 1).

Consequences after adenoidectomy

After adenoidectomy and facilitation of nasal breathing, accelerated mandibular growth and closure of the mandibular plane angle, but not the maxillary plane angle, have been reported, however, with a large variation in response (Linder-Aronson *et al.*, 1986; Woodside *et al.*, 1991). In a more detailed analysis, anterior face height was found to be unaffected and remained longer in the initially large adenoid subjects than in healthy controls 5 years after adenoidectomy. In the same study, growth of the mandibular ramus and condylar process of adenoidectomy patients was found to be greater than that in the control subjects (Kerr *et al.*, 1989). The changes have, as a rule, been explained by alteration in tongue position and autorotation of the mandible (Linder-Aronson, 1979; Figure 2). However, a decrease in the mandibular plane angle necessitates more growth in posterior face height/ramus height than anteriorly, since intrusion of maxillary teeth may only be possible with the use of intrusive devices or maxillary impaction with surgery (Woodside *et al.*, 1991).

Obstructive sleep apnoea

In all individuals, muscular activity is reduced and upper airway resistance increased during sleep compared with wakefulness (Worsnop *et al.*, 2000). This does not have a

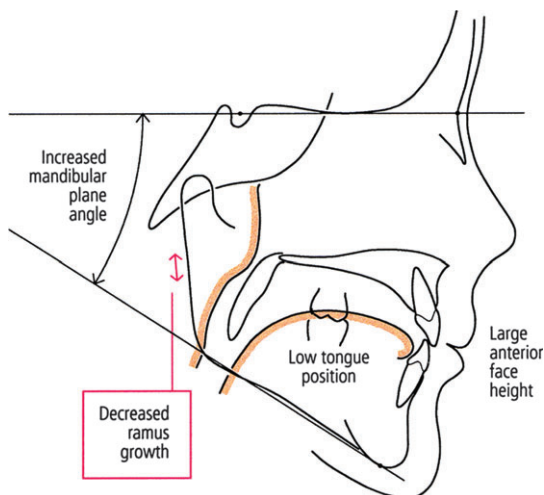


Figure 1 Tracing of a child with large adenoids. Because of mouth breathing, tongue position in the oral cavity is low and the balance between forces from the cheeks and tongue is different compared with healthy children. This leads to a lower mandibular position and extended head posture. Cephalometrically a large anterior face height and increased mandibular plane angle can be noted (adapted from Linder-Aronson, 1970, 1979). In addition, according to the present hypothesis, because of abnormal nocturnal growth hormone secretion, ramus growth is less than that in healthy subjects.

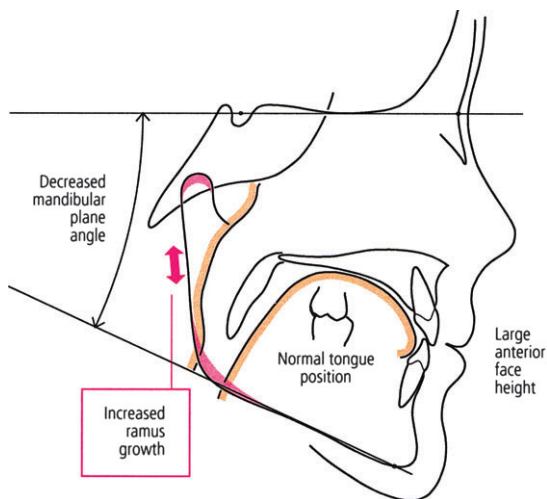


Figure 2 Tracing of a child after adenotonsillectomy. Because of normalization of breathing and tongue position, the mandibular plane angle has been found to decrease and mandibular growth accelerated with no changes in anterior face height (adapted from Linder-Aronson *et al.*, 1986; Woodside *et al.*, 1991). In addition, according to the present hypothesis, because of normalization of secretion of growth hormone and its mediators, accelerated mandibular growth and change in its growth direction can be explained particularly by increased ramus growth. In other words, more intensive growth in the condylar cartilage and/or in the lower border of the mandible at the muscular attachment area.

notable effect on breathing in anatomically and functionally 'healthy' individuals. On the other hand, reduction of muscular tonus in children with large adenoids and tonsils, or with other underlying abnormal upper airway anatomy,

may lead to airway obstruction and eventually to obstructive sleep apnoea (OSA). Interestingly, these children have been found to have similar craniofacial characteristics as adenoid face children (Guilleminault *et al.*, 1996; Shintani *et al.*, 1997; Agren *et al.*, 1998; Zucconi *et al.*, 1999; Kawashima *et al.*, 2000, 2002; Zettergren-Wijk *et al.*, 2006). The first treatment of choice of OSA children is removal of adenoids and tonsils (Nieminen, 2002; Guilleminault *et al.*, 2004). It can thus be postulated that some children with a clinical diagnosis of an adenoid face could nowadays be diagnosed as having OSA. Of particular interest is the recent cephalometric study on 5-year-old children with polysomnographically verified OSA (Zettergren-Wijk *et al.*, 2006). This study showed that OSA children have a different facial morphology compared with age-matched controls. The mandibular plane angle was found to be posteriorly inclined, anterior face height to be greater, and posterior face height smaller, in the OSA than in the control children. At the 5-year follow-up after adenotonsillectomy, no major craniofacial differences were noted. In a closer look at the growth changes it becomes evident that anterior face height remained greater in the OSA children than in the control children (difference on average 2.5 mm), but it increased on average by a comparable amount in both groups of children. Yet, the mandibular plane angle was decreased in the OSA children. This may be explained by the described greater posterior face height growth (ramus growth) in the OSA than in the control children (OSA children 5 mm, control children 3 mm).

OSA children with large adenoids and tonsils have also been found to have somatic growth impairment due to abnormal nocturnal growth hormone (GH) secretion (Goldstein *et al.*, 1987; Bar *et al.*, 1999; Nieminen *et al.*, 2002). Following adenotonsillectomy, a significant increase in the serum levels of GH mediators, i.e. insulin-like growth factor I (IGF I) and its binding protein, has been reported. Consequently, normalization and even catch-up of somatic growth have been observed (Bar *et al.*, 1999; Nieminen *et al.*, 2002). Could the craniofacial characteristics, particularly the height of the mandibular ramus, in adenoid face children and changes after removal of adenoids and tonsils, be partly explained by changes found in the hormonal status?

Growth of the mandibular ramus

Endochondral bone formation in the condylar cartilage and bone apposition in the lower border of the mandible (gonial region) contribute to the growth in height of the mandibular ramus. Studies on mandibular condylar cartilage have shown that the cartilage not only is a passive growth site, but also is endowed with some tissue-separating potential (Coprav *et al.*, 1986; Rönning and Peltomäki, 1991). It has also been maintained to be active in displacing the condylar process downwards (Kantomaa, 1984). In addition, the mandibular condylar cartilage seems to be a target and

production site of hormonal agents as evidenced by IGF I receptor and IGF I messenger RNA expression in the cartilage (Visnapuu *et al.*, 2001, 2002). Patients with GH deficiency have been shown to have a small posterior face height compared with age and gender-matched healthy controls (Pirinen *et al.*, 1994; Karsila-Tenovuo *et al.*, 2001). Furthermore, administration of GH to patients with GH deficiency, such as those with Turner syndrome or in bone marrow transplant patients, has clearly shown that mandibular growth, and particularly mandibular ramus growth, is accelerated compared with control children (Dahlöf *et al.*, 1991; Rongen-Westerlaken *et al.*, 1993; Simmons, 1999; Forsberg *et al.*, 2002). The increase in mandibular ramus height by GH can be explained by two possibilities. Firstly, increased endochondral bone formation in the condylar cartilage and secondly, increased bone apposition in the lower border of the mandible through the anabolic effects of GH on the masseter and medial pterygoid muscles (Vogl *et al.*, 1993).

Conclusion

Taking into account the recent evidence from children with OSA, it can be postulated that the craniofacial structure before, and its change after adenotonsillectomy, in patients with large adenoids and tonsils (classically, regarded as mouth breathing patients) are not only caused by a mechanistic alteration in the muscular balance and head and tongue position due to the change in the mode of breathing but also caused by a more complex sequence of epigenetic events. Because of abnormal nocturnal secretion of GH and its mediators in children with obstructed breathing, mandibular ramus growth is less than that in healthy subjects (Figure 1). After normalization of hormonal status, ramus growth is enhanced by more intensive endochondral bone formation in the condylar cartilage and/or by appositional bone growth in the lower border of the mandible at the muscular attachment area (Figure 2). This growth enhancement would, in part, explain the noted acceleration in the growth of the mandible and change in its growth direction after alteration in the mode of breathing following adenotonsillectomy. Finally, it is noteworthy that in many cases the growth acceleration is not sufficient to solve the already formed malocclusion and skeletal discrepancy, and therefore, orthodontic treatment is also indicated.

Address for correspondence

Timo Peltomäki
Clinic for Orthodontics and Pediatric Dentistry
Center for Dental and Oral Medicine
University of Zurich
Plattenstrasse 11
CH-8032 Zurich
Switzerland
E-mail: timo.peltomaki@zzmk.uzh.ch

References

- Agren K, Norlander B, Linder-Aronson S, Zettergren-Wijk L, Svanborg E 1998 Children with nocturnal upper airway obstruction: postoperative orthodontic and respiratory improvement. *Acta Otolaryngologica* (Stockholm) 118: 581–587
- Bar A, Tarasiuk A, Segev Y, Phillip M, Tal A 1999 The effect of adenotonsillectomy on serum insulin-like growth factor-I and growth in children with obstructive sleep apnea syndrome. *Journal of Pediatrics* 135: 76–80
- Behlfelt K, Linder-Aronson S, McWilliam J, Neander P, Laage-Hellman J 1990 Cranio-facial morphology in children with and without enlarged tonsils. *European Journal of Orthodontics* 12: 233–243
- Copray J C, Jansen H W, Duterloo H S 1986 Growth and growth pressure of mandibular condylar and some primary cartilages of the rat *in vitro*. *American Journal of Orthodontics and Dentofacial Orthopedics* 90: 19–28
- Dahlöf G *et al.* 1991 Craniofacial growth in bone marrow transplant recipients treated with growth hormone after total body irradiation. *Scandinavian Journal of Dental Research* 99: 44–47
- Forsberg C M, Krekmanova L, Dahlöf G 2002 The effect of growth hormone therapy on mandibular and cranial base development in children treated with total body irradiation. *European Journal of Orthodontics* 24: 285–292
- Goldstein S J, Wu R H, Thorpy M J, Shprintzen R J, Marion R E, Saenger P 1987 Reversibility of deficient sleep entrained growth hormone secretion in a boy with achondroplasia and obstructive sleep apnea. *Acta Endocrinologica* (Copenhagen) 116: 95–101
- Guilleminault C, Li K K, Khramtsov A, Pelayo R, Martinez S 2004 Sleep disordered breathing: surgical outcomes in prepubertal children. *Laryngoscope* 114: 132–137
- Guilleminault C, Pelayo R, Leger D, Clerck A, Bocian R C 1996 Recognition of sleep-disordered breathing in children. *Pediatrics* 98: 871–882
- Kantamaa T 1984 The role of the mandibular condyle in the facial growth. *Proceedings of the Finnish Dental Society* 80: 1–57
- Karsila-Tenovuo S *et al.* 2001 Disturbances in craniofacial morphology in children treated for solid tumors. *Oral Oncology* 37: 586–592
- Kawashima S *et al.* 2000 Cephalometric comparisons of craniofacial and upper airway structures in young children with obstructive sleep apnea syndrome. *Ear, Nose, and Throat Journal* 79: 499–506
- Kawashima S, Peltomäki T, Sakata H, Mori K, Happonen R P, Rönning O 2002 Craniofacial morphology in preschool children with sleep-related breathing disorder and hypertrophy of tonsils. *Acta Paediatrica* 91: 71–77
- Kerr W J S, McWilliam J S, Linder-Aronson S 1989 Mandibular form and position related to changed mode of breathing—a five-year longitudinal study. *Angle Orthodontist* 59: 91–96
- Linder-Aronson S 1970 Adenoids: their effect on mode of breathing and nasal airflow and their relationship to characteristics of the facial skeleton and the dentition. *Acta Oto-Laryngologica. Supplementum* 265: pp.1-132
- Linder-Aronson S 1979 Respiratory function in relation to facial morphology and the dentition. *British Journal of Orthodontics* 6: 59–71
- Linder-Aronson S, Woodside D G, Lundström A 1986 Mandibular growth direction following adenoidectomy. *American Journal of Orthodontics* 89: 273–284
- McNamara Jr J A 1981 Influence of respiratory pattern on craniofacial growth. *Angle Orthodontist* 51: 269–300
- Nieminen P 2002 Snoring and obstructive sleep apnea in young children. Thesis, University of Oulu, Oulu, Finland
- Nieminen P, Löppönen T, Tolonen U, Lanning P, Knip M, Löppönen H 2002 Growth and biochemical markers of growth in children with snoring and obstructive sleep apnea. *Pediatrics* 109: e55
- Pirinen S, Majurin A, Lenko H L, Koski K 1994 Craniofacial features in patients with deficient and excessive growth hormone. *Journal of Craniofacial Genetics and Developmental Biology* 14: 144–152

- Rongen-Westerlaken C *et al.* 1993 Effect of growth hormone treatment on craniofacial growth in Turner's syndrome. *Acta Paediatrica* 82: 364–368
- Rønning O, Peltomäki T 1991 Growth potential of the rat mandibular condyle as an isogeneic transplant traversing the interparietal suture. *Archives of Oral Biology* 36: 203–210
- Shintani T, Asakura K, Kataura A 1997 Evaluation of the role of adenotonsillar hypertrophy and facial morphology in children with obstructive sleep apnea. *Journal for Oto-Rhino-Laryngology and its Related Specialties* 59: 286–291
- Simmons K E 1999 Growth hormone and craniofacial changes: preliminary data from studies in Turner's syndrome. *Pediatrics* 104: 1021–1024
- Solow B, Kreiborg S 1977 Soft-tissue stretching: a possible control factor in craniofacial morphogenesis. *Scandinavian Journal of Dental Research* 85: 505–507
- Solow B, Siersbæk-Nielsen S, Greve E 1984 Airway adequacy, head posture, and craniofacial morphology. *American Journal of Orthodontics* 86: 214–223
- Subtelny J D 1954 The significance of adenoid tissue in orthodontia. *Angle Orthodontist* 24: 59–69
- Trotman C A, McNamara Jr J A, Dibbets J M, van der Weele L T 1997 Association of lip posture and the dimensions of the tonsils and sagittal airway with facial morphology. *Angle Orthodontist* 67: 425–432
- Vig K W L 1998 Nasal obstruction and facial growth: the strength of evidence for clinical assumptions. *American Journal of Orthodontics and Dentofacial Orthopedics* 113: 603–611
- Visnapuu V, Peltomäki T, Rønning O, Vahlberg T, Helenius H 2001 Growth hormone and insulin-like growth factor I receptors in the temporomandibular joint of the rat. *Journal of Dental Research* 80: 1903–1907
- Visnapuu V, Peltomäki T, Rønning O, Syrjänen S 2002 Distribution of insulin-like growth factor-I mRNA in the mandibular condyle and rib cartilage of the rat during growth. *Archives of Oral Biology* 47: 791–798
- Vogl C, Atchley W R, Cowley D E, Crenshaw P, Murray J D, Pomp D 1993 The epigenetic influence of growth hormone on skeletal development. *Growth, Development, and Aging* 57: 163–182
- Warren D W, Spalding P M 1991 Dentofacial morphology and breathing: a century of controversy. In: Melsen B (ed.). *Current controversies in orthodontics*. Quintessence Publishing, Chicago, pp. 45–76
- Woodside D G, Linder-Aronson S, Lundström A, McWilliam J 1991 Mandibular and maxillary growth after changed mode of breathing. *American Journal of Orthodontics and Dentofacial Orthopedics* 100: 1–18
- Worsnop C, Kay A, Kim Y, Trinder J, Pierce R 2000 Effect of age on sleep onset-related changes in respiratory pump and upper airway muscle function. *Journal of Applied Physiology* 88: 1831–1839
- Zettergren-Wijk L, Forsberg C M, Linder-Aronson S 2006 Changes in dentofacial morphology after adeno-/tonsillectomy in young children with obstructive sleep apnoea—a 5-year follow-up study. *European Journal of Orthodontics* 28: 319–326
- Zucconi M 1999 Craniofacial modifications in children with habitual snoring and obstructive sleep apnoea: a case-control study. *European Respiratory Journal* 13: 411–417