

# Ankyloglossia as a risk factor for maxillary hypoplasia and soft palate elongation: A functional – morphological study

A. J. Yoon<sup>1</sup>  | S. Zaghi<sup>2,3</sup> | S. Ha<sup>4</sup> | C. S. Law<sup>1</sup> | C. Guilleminault<sup>5</sup> | S. Y. Liu<sup>2</sup>

<sup>1</sup>Sections of Pediatric Dentistry and Orthodontics, Division of Growth and Development, UCLA School of Dentistry, Los Angeles, CA, USA

<sup>2</sup>Division of Sleep Surgery, Department of Otolaryngology, School of Medicine, Stanford University, Stanford, CA, USA

<sup>3</sup>UCLA Health, Santa Monica, CA, USA

<sup>4</sup>UCLA School of Dentistry, Los Angeles, CA, USA

<sup>5</sup>Sleep Medicine Division, Stanford Outpatient Medical Center, Redwood City, CA, USA

## Correspondence

A. J.-S. Yoon, Section of Pediatric Dentistry and Orthodontics, Division of Growth and Development, UCLA School of Dentistry, Los Angeles, CA, USA.  
Email: jungdds@gmail.com

## Structured Abstract

**Objectives:** To characterize associations between restricted tongue mobility and maxillofacial development.

**Setting and Sample Population:** Cross-sectional cohort study of 302 consecutive subjects from an orthodontic practice.

**Material and Methods:** Tongue mobility (measured with tongue range of motion ratio [TRMR] and Kotlow free tongue measurement) was correlated with measurements of the maxillofacial skeleton obtained from dental casts and cephalometric radiographs.

**Results:** Tongue range of motion ratio and Kotlow measures of restricted tongue mobility were associated with (i) ratio of maxillary intercanine width to canine arch length, (ii) ratio of maxillary intermolar width to canine arch length and (iii) soft palate length. Restricted tongue mobility was not associated with hyoid bone position or Angle's skeletal classification.

**Conclusions:** Restricted tongue mobility was associated with narrowing of the maxillary arch and elongation of the soft palate in this study. These findings suggest that variations in tongue mobility may affect maxillofacial development.

## KEYWORDS

ankyloglossia, frenulum, maxillofacial development, myofunctional dysfunction

## 1 | INTRODUCTION

The tongue may play a role in developmental of the maxillofacial skeleton.<sup>1,2</sup> During development, the tongue maintains a balance of forces between the soft tissue structures and the growing maxillofacial skeleton.<sup>3,4</sup> When tongue mobility is impaired by congenital or developmental conditions (eg microglossia, aglossia, tongue hemiatrophy, cleft tongue, bifid tongue,<sup>5</sup> oromotor dystonia of cerebral palsy,<sup>6</sup> oromotor dyspraxia of William's syndrome<sup>7</sup>), there are developmental consequences for the maxillofacial skeleton.<sup>8,4</sup> The most common congenital disorder affecting tongue mobility is lingual frenulum restriction resulting in ankyloglossia, with an incidence of approximately 4.8% in the newborn.<sup>9</sup>

Tongue mobility is influenced by the length and thickness of the lingual frenulum, which extends from the ventral surface of the tongue to the floor of the mouth.<sup>10</sup> During deglutition, the tongue pushes onto the palate,<sup>11</sup> and the lingual frenulum determines the extent to

which the tongue can elevate.<sup>3</sup> Upward pressure of the dorsum of the tongue against the palate during swallowing helps form the width and shape of the hard palate. A short-lingual frenulum limits upward movement such that during deglutition the tongue thrusts anteriorly instead of upward against the hard palate. This has been clinically associated with reduced palatal width.<sup>3</sup> The palatal bones form the roof of the oral cavity and the floor of the nasal cavity. Thus, maxillary constriction is also accompanied by narrowing of the nasal cavity, resulting in nasal obstruction, mouth breathing and sleep-disordered breathing.<sup>12</sup>

Studies have explored the influence of the tongue and lingual frenulum on anomalies such as mandibular prognathism, maxillary protrusion and anterior open bite.<sup>3,13,1,14</sup> However, there remains the need for investigator-blinded, controlled studies examining the association of lingual frenulum and tongue posture on development of the maxilla, as it defines the dimension and patency of the nasal and oropharyngeal airway. This study is a functional-morphological investigation of

the association between tongue mobility and maxillofacial development in a large cohort.

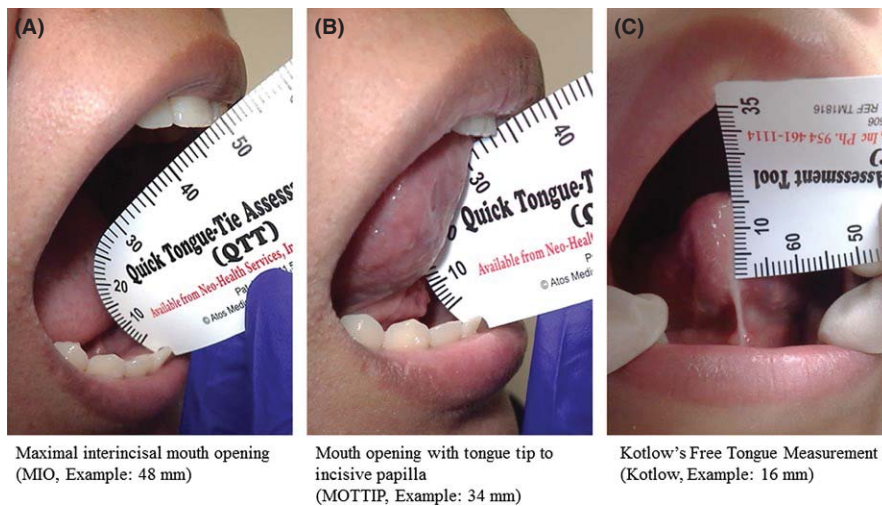
## 2 | MATERIALS AND METHODS

This was a cross-sectional cohort study of 302 consecutive subjects evaluated in a private orthodontic practice (AY, Los Angeles, CA, USA) from July to September 2016. Subjects aged six and over were invited to participate. Exclusion criteria were as follows: history of frenectomy, orthodontia, maxillary expansion, maxillofacial surgery, missing or ectopic eruption of canines or first molars and functional trismus. The study involved three main components: (i) functional measurement of tongue mobility, (ii) anatomical measurement of the maxillary and mandibular arches using dental casts and (iii) radiographic measurement using lateral cephalometric radiographs. The following demographic data were collected the following: age, gender, height (cm), weight (kg) and BMI (kg/m<sup>2</sup>). Subjects who participated in the study provided written informed consent for their examination findings, dental casts, radiologic studies and personal health information

to be used for research purposes. The study protocol was approved by the institutional review board (IRB) of University of California, Los Angeles (IRB#16-001286).

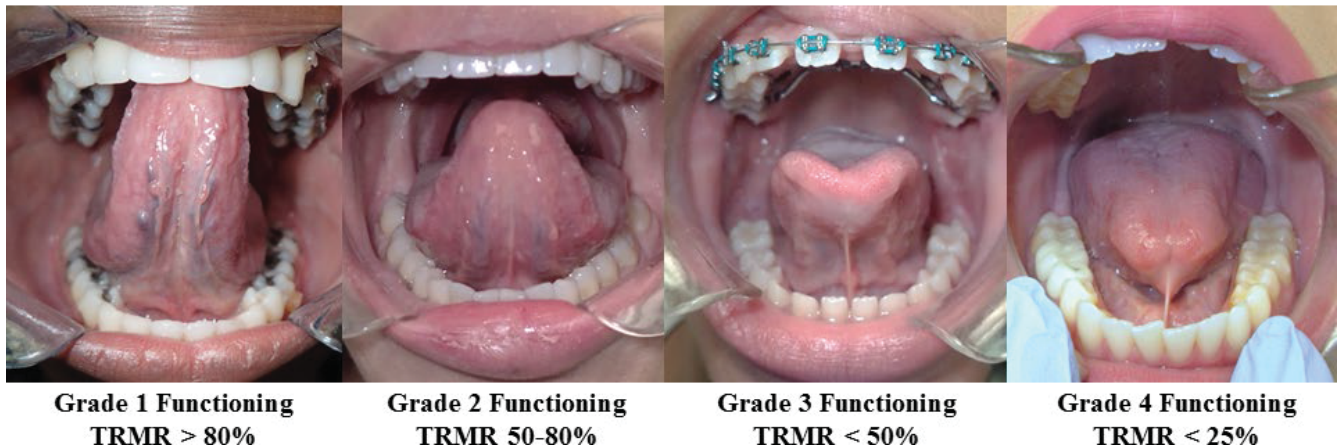
### 2.1 | Tongue mobility measurements

Assessment of the lingual frenulum and tongue mobility was performed by two measures: (i) Tongue Range of Motion Ratio (TRMR) and (ii) Kotlow free tongue measurement. A single rater performed all measurements, and the average of three consecutive measurements was obtained. TRMR is calculated as the mouth opening with tongue tip to maxillary incisive papillae (MOTTIP) divided by maximal interincisal mouth opening (MIO). Our methods of measuring MIO and MOTTIP have previously been published (Figure 1). Briefly, functional TRMR as related to MIO grading scale is rated as follows: Grade 1 = >80% (complete tongue mobility), Grade 2 = 50%-80% (average to mildly restricted tongue mobility), Grade 3 = <50% (moderately restricted tongue mobility), Grade 4 = < 25% (severely restricted tongue mobility)<sup>15</sup> (Figure 2). Kotlow free tongue measurement is obtained by measuring the length of the ventral surface



**FIGURE 1** Examples of tongue functioning and length measurements using the Quick Tongue Tie Assessment Tool (QTT): Mouth opening with tongue tip to incisive papilla (MOTTIP), maximal interincisal mouth opening (MIO) and Kotlow's free tongue measurement. Tongue range of motion ratio (TRMR) is defined as the ratio of MOTTIP to MIO

### Functional classification of ankyloglossia based on tongue range of motion ratio (TRMR)

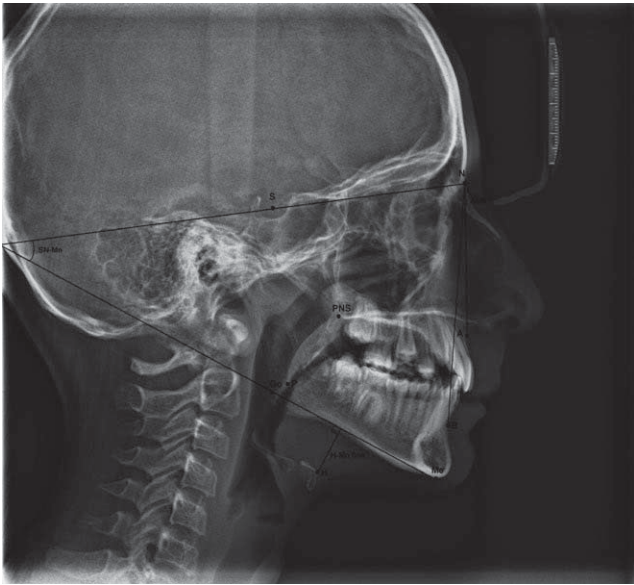


**FIGURE 2** Examples of varying degrees of ankyloglossia categorized by tongue range of motion ratio (TRMR) grading (ratio of MOTTIP to interincisal mouth opening [MIO])

of the tongue (while in full extension) from the insertion of the lingual frenulum to the tongue tip.<sup>16</sup>

## 2.2 | Cephalometric analysis (Figure 3)

Lateral cephalogram performed with subjects in natural head position was obtained prior to initiation of orthodontic treatment. The radiographs were analysed with Dolphin Image Software 9.0 (Chatsworth, CA, USA).

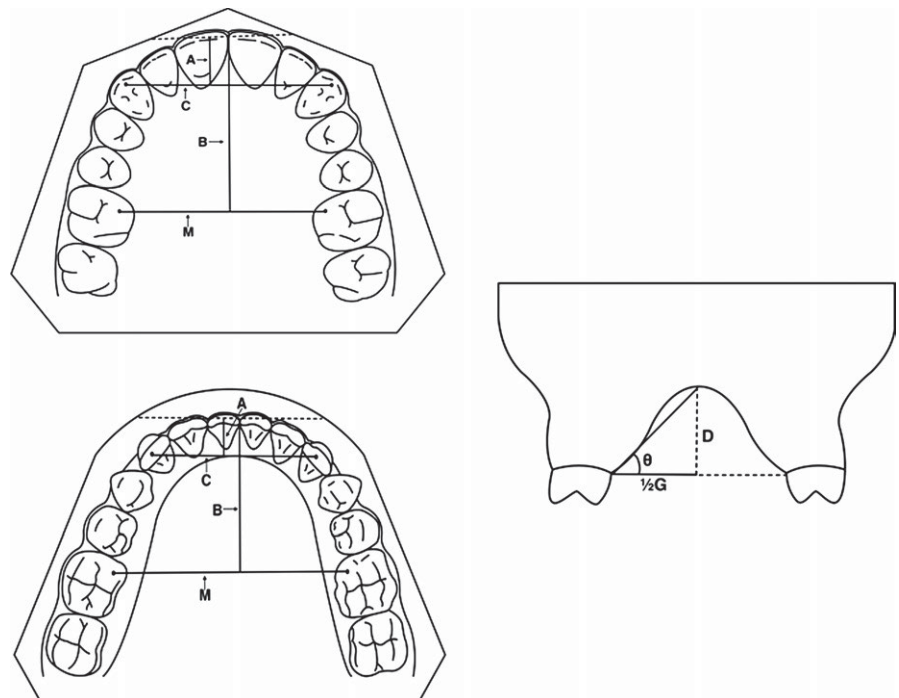


**FIGURE 3** Points and measurements for the cephalometric analysis. Nasion (N), point A (A), sella (S), menton (Me), hyoid (H), posterior nasal spine (PNS), tip of soft palate (P), gonion (Go), posterior nasal spine (PNS)

The following two angular and linear parameters were measured as follows: (i) ANB: angle formed between points A, N, and B; (ii) SN- Mn: angle formed between the SN line and mandibular plane (mn); (iii) H- Mn (mm): perpendicular distance from hyoid (H) to mandibular plane (Mn) which was drawn between gonion (Go) and menton (Me); (iv) PNS- P (mm): distance between posterior nasal spine (PNS) and tip of soft palate (P), also known as soft palate length. Subjects were classified based on the following ANB angle criteria: Skeletal Class I:  $0^{\circ}$  to  $4^{\circ}$ ; Skeletal Class II:  $>4^{\circ}$ ; Skeletal Class III:  $<0^{\circ}$ . These measurements were performed by two raters blinded to grading of tongue mobility, and the average of three measurements was obtained.

## 2.3 | Orthodontic study models (Figure 4)

Stone dental casts were obtained prior to initiation of orthodontic treatment. The following measurements were obtained using a digital calliper, with the average of three consecutive measurements recorded for each dental arch (maxillary and mandibular): intercanine width (C), canine arch length (A), intermolar width (M) and molar arch length (B). The mesiolingual cusp tips of first molars were used as the reference point for the molar measurements. In addition, for the maxillary cast, the depth of the deepest point of palatal vault (D) and the distance between the gingival margins of the first molars (G) was also recorded. The following parameters, derived from the raw measurements, were then used for analysis: (i) ratio of maxillary and mandibular intercanine width to canine arch length; (ii) ratio of maxillary and mandibular intermolar width to molar arch length; (iii) palatal slope as calculated by the following formula:  $\theta = \tan^{-1} \left( \frac{D}{\frac{1}{2}G} \right)$ . Two calibrated raters, blinded to grading of tongue mobility, performed the measurements.



**FIGURE 4** Measurements obtained from maxillary and mandibular dental casts. A-Canine arch length from line connecting central incisors to line connecting canine cusp tips, B-Molar arch length from line connecting central incisors to line connecting 1<sup>st</sup> molar ML cusps, C-Intercanine width between canine cusp tips, M-Intermolar width between 1<sup>st</sup> molar ML cusps, D-Depth of deepest point of palatal vault, G-Distance between gingival margins of first molars,  $\theta$ -Palatal slope

**TABLE 1** Patient demographics, dental cast measurements and cephalometric analysis by tongue range of motion ratio grade

		TRMR Grade					P-Value
		All	Grade 1	Grade 2	Grade 3	Grade 4	
			>80%	50%-80%	<50%	<25%	
N	Number	302	19	226	53	4	
	% Total	100%	6.3%	74.8%	17.5%	1.3%	
Patient demographics							
Gender	Male	115 (38.1%)	7 (36.9%)	82 (36.3%)	23 (43.4%)	3 (75.0%)	.1744
	Female	187 (61.9%)	12 (63.1%)	144 (63.7%)	30 (56.6%)	1 (25.0%)	
Age (y)	Mean	18.1	18.3	18.0	18.9	14.5	.8103
	Std dev	9.4	10.6	9.1	10.5	3.9	
Weight (kg)	Mean	56.3	58.9	55.7	57.9	57.5	.7474
	Std dev	17.1	24.4	16.0	19.2	14.3	
Height (inches)	Mean	63.0	60.9	63.2	62.8	66.0	.1857
	Std dev	5.2	7.9	4.9	5.1	6.3	
BMI (kg/m <sup>2</sup> )	Mean	21.6	23.7	21.3	22.2	20.1	.1404
	Std dev	5.0	6.6	4.7	5.4	1.7	
Cast measurements							
Ratio Mx C W:AL	Mean	3.5	3.6	3.6	3.1	3.0	.0015**, <sup>‡</sup>
	Std dev	0.9	0.6	0.9	0.7	0.5	
Ratio Mx M W:AL	Mean	1.2	1.2	1.2	1.1	1.1	.0070**
	Std dev	0.1	0.1	0.1	0.1	0.1	
Ratio Mn C W:AL	Mean	4.7	4.9	4.8	4.4	4.9	.5446
	Std dev	1.5	1.2	1.6	1.2	0.8	
Ratio Mn M W:AL	Mean	1.3	1.3	1.2	1.3	1.4	.2024
	Std dev	0.2	0.1	0.1	0.2	0.2	
Palatal slope	Mean	35.3	32.4	35.1	36.9	41.4	.0118*
	Std dev	6.5	6.5	6.2	7.5	1.7	
Cephalometric analysis							
SN-Mn angle	Mean	36.0	36.9	35.7	36.6	40.8	.2640
	Std dev	6.1	7.8	5.8	6.4	7.0	
H-Mn line	Mean	12.7	13.4	12.4	13.3	15.7	.4038
	Std dev	5.2	7.5	4.8	5.7	5.4	
PNS-P line	Mean	31.6	30.3	31.3	33.5	34.1	.0137* <sup>‡</sup>
	Std dev	5.0	6.2	4.6	5.6	2.8	

TRMR, Tongue range of motion ratio; Mx, Maxillary; Mn, Mandibular; C, Canine; M, Molar; W:AL, Ratio of Width to Arch Length; SN-Mn angle, Mandibular plane angle; the angle between SN line, where S, sella and N, nasion and Mn plane, drawn between gonion (Go) and menton (Me), H-Mn (mm), perpendicular distance from hyoid (H) to mandibular plane (Mn); PNS-P line, distance from posterior nasal spine (PNS) and tip of soft palate (P).

\*Statistical significance with  $P$ -value  $<.05$ .

\*\*Statistical significance with  $P$ -value  $<.01$  on univariate analysis.

<sup>‡</sup>Statistical significance with  $P < .01$  on multivariate analysis with a Standard Least Squares Regression Model.

## 2.4 | Data collection

The study data were collected and managed using REDCap electronic data capture tools hosted at the UCLA Clinical and Translational Science Institute. REDCap (Research Electronic Data Capture) is a secure, web-based application designed to support data capture for research studies.<sup>17</sup> Two raters assessed cast and cephalometric measurements and

one rater assessed tongue mobility (MOTTIP), Kotlow free tongue length, maximal interincisal mouth opening (MIO) measurements. Measurement calibration was performed with an initial sample of 10 cases in three repeated trials. Inter-rater (by rater) and intrarater (by trial) reliabilities were assessed with the intraclass correlation coefficient (ICC), measurement error (ME) and coefficient of variation (CV) statistics using JMP Pro 12.0 (Measurement System Analysis, EMP results, EMP Gauge R&R results).<sup>18</sup>

**TABLE 2** Patient demographics, dental cast measurements and cephalometric analysis by kotlow classification. Please refer to Table 1 legend

		Kotlow classification					P-Value
		Normal > 16 mm	Class 1 12-16 mm	Class 2 8-11 mm	Class 3 3-7 mm	Class 4 <3 mm	
N	Number	142	123	33	3	1	
	% Total	47.0%	40.7%	10.9%	0.99%	0.33%	
Patient demographics							
Gender	Male	51 (35.9%)	47 (38.2%)	14 (42.4%)	2 (66.7%)	1 (100%)	.3752
	Female	91 (64.1%)	76 (61.8%)	19 (57.6%)	1 (33.3%)	0 (0%)	
Age (y)	Mean	19.2	17.3	16.9	13.0	19.0	.3454
	Std dev	9.4	9.3	9.9	3.0		
Weight (kg)	Mean	58.3	54.6	54.0	53.0	70.9	.3383
	Std dev	17.1	16.8	18.4	13.6		
Height (inches)	Mean	63.3	62.8	62.1	64.3	71.0	.3851
	Std dev	4.9	5.2	5.8	6.5		
BMI (kg/m <sup>2</sup> )	Mean	22.2	21.1	21.1	19.5	21.8	.4142
	Std dev	5.0	5.0	4.9	1.5		
Cast measurements							
Ratio Mx C W:AL	Mean	3.7	3.4	3.0	2.8	3.4	.0011***‡
	Std dev	0.9	0.8	0.6	0.5		
Ratio Mx M W:AL	Mean	1.2	1.2	1.1	1.2	1.1	.0027**
	Std dev	0.1	0.1	0.1	0.1		
Ratio Mn C W:AL	Mean	4.7	4.8	4.2	4.8	5.0	.4236
	Std dev	1.4	1.6	1.3	1.0		
Ratio Mn M W:AL	Mean	1.3	1.2	1.2	1.3	1.5	.1898
	Std dev	0.1	0.2	0.2	0.2		
Palatal slope	Mean	35.0	35.1	36.5	42.1	39.2	.2907
	Std dev	6.1	6.5	8.1	1.1		
Cephalometric analysis							
SN-Mn angle	Mean	36.4	35.5	35.1	43.8	31.5	.1061
	Std dev	6.0	6.4	5.1	4.0		
H-Mn line	Mean	12.6	12.5	13.5	14.5	19.4	.5591
	Std dev	5.1	5.1	5.5	5.8		
PNS-P line	Mean	30.9	31.5	34.9	33.3	36.3	.0011***‡
	Std dev	4.7	5.0	5.3	2.9		

The results indicated measurement reliabilities between 98.0% and 99.6% across all domains.

## 2.5 | Statistical analysis

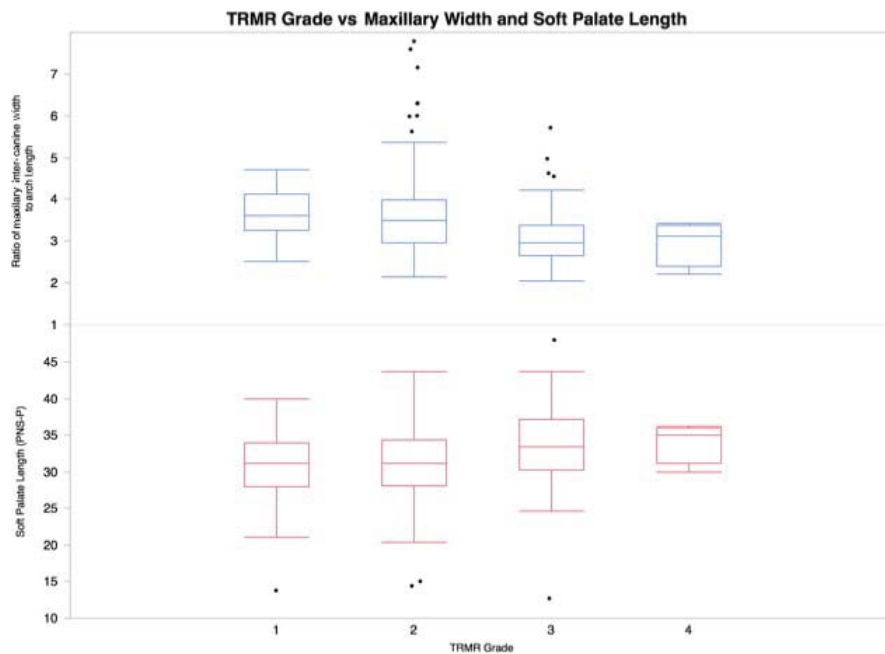
Statistical analyses were performed using JMP Pro 12 (SAS Institute Inc., Cary, NC, USA). Continuous variables are summarized as mean (M) ± standard deviation (SD). Categorical variables are summarized as frequencies and percentages. Univariate analysis with Pearson's Chi Square or independent t test (continuous variables) was performed to assess for nominal or continuous covariates of tongue measurements

including age, gender, height, weight and BMI. Due to the testing of multiple variables for each outcome, a two-tailed *P*-value < .01 was selected as the cut-off for statistical significance.

## 3 | RESULTS

Our study included 302 subjects with age ranging from 6 to 67 years. Demographic factors included age: 18.1 ± 9.4 years (M ± SD); gender: 61.9% female; weight: 56.3 ± 17.1 kg; height: 63.0 ± 5.2 inches; BMI: 21.6 ± 5.0 kg/m<sup>2</sup>. Ethnicities include Asian 39.1%, Hispanic 35.8%,





**FIGURE 5** Tongue range of motion ratio (TRMR) Grade vs Maxillary Width and Soft Palate Length. Box and whisker plots are displayed outlining the 95% confidence intervals, median, interquartile ranges and outliers for the distribution of the Ratio Mx C W: AL and PNS-P measurements for the entire overall sample of patients

White 15%, Black 8%. This sample includes 47 children (ages 6-11), 160 adolescents (age 12-17), 71 young adults (age 18-35), 23 adults (age 36-64) and 1 senior (age > 65). The average TRMR for the entire cohort was  $62.1 \pm 13.8$  (mean  $\pm$  SD); the average Kotlow free tongue length was  $17.2 \pm 5.9$  mm. (Table 1 and 2).

The distribution of TRMR was as follows: Grade 1 = 6.3% (n = 19), Grade 2 = 74.8% (n = 226), Grade 3 = 17.5% (n = 53), Grade 4 = 1.3% (n = 4). The distribution of Kotlow classification was as follows: Normal = 47.0% (n = 142), Class 1 = 40.7% (n = 123), Class 2 = 10.9% (n = 33), Class 3 = 0.99% (n = 3), Class 4 = 0.33% (n = 1). There were no significant differences in age, gender, weight, height or BMI.

Four factors achieved or approached statistical significance on univariate analysis for association with TRMR (Table 1). Higher TRMR grade was associated with decreased ratio of maxillary intercanine width to canine arch length (Ratio Mx C W: AL), decreased ratio of maxillary intermolar width to molar arch length (Ratio Mx M W:AL), increased palatal slope measurements, and longer soft palate length (PNS-P line). In the multivariate analysis with Standard Least Squares Regression Model, two factors were found to be independently associated with TRMR, namely, Ratio MxC W:D =  $4.41 \pm 0.88$ ,  $P < .0001$ ; PNS-P =  $-0.45 \pm 0.15$ ,  $P = .0037$ . See Figures 5 and 6.

Similar factors achieved statistical significance on univariate analysis for an association with ankyloglossia based on Kotlow free tongue length measurements (Table 2). In the multivariate analysis with Standard Least Squares Regression Model, Ratio Mx C W: AL and PNS-P line were found to be independently associated with Kotlow free tongue measurement (Beta-estimate  $\pm$  Standard error: Ratio MxC W:AL =  $1.36 \pm 0.39$ ,  $P = .0005$  and PNS-P =  $-0.19 \pm 0.06$ ,  $P = .0050$ ). See Tables 1 and 2 for further details.

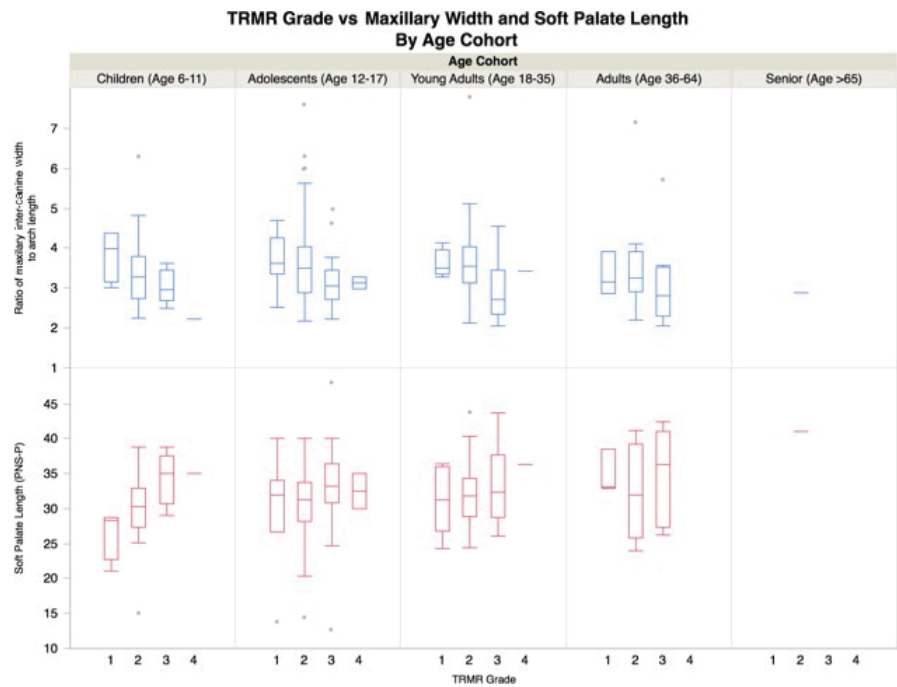
Tongue range of motion ratio and Kotlow Classification were not associated with either dental or skeletal classification ( $P > .05$ ). See Figure 7.

## 4 | DISCUSSION

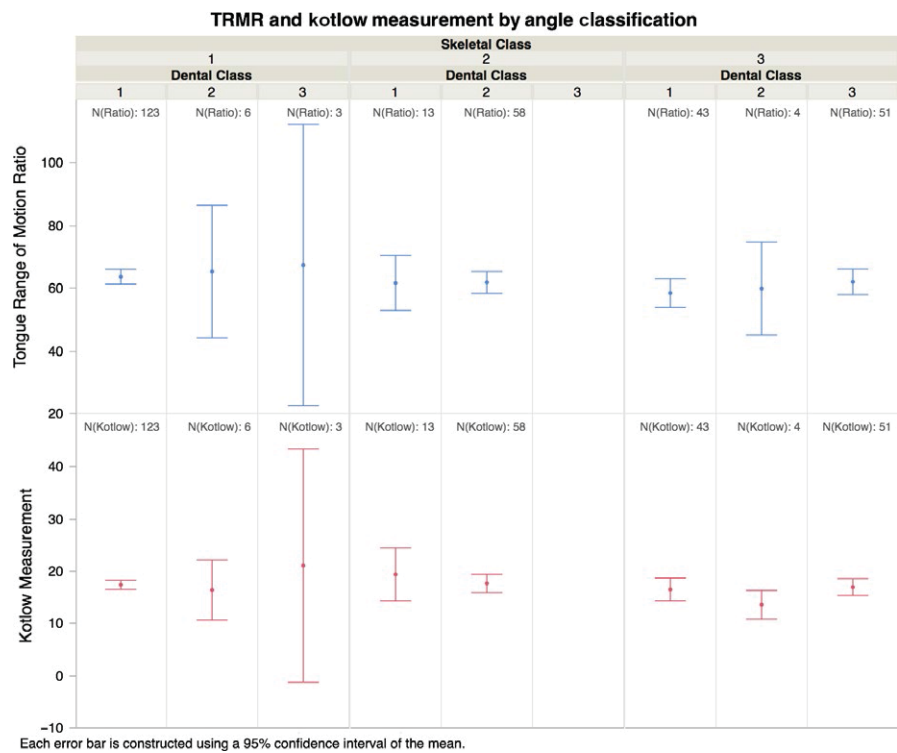
There are four main findings from this functional-morphological study examining the association between tongue mobility and maxillofacial development. First, TRMR and Kotlow measures of reduced tongue mobility are both associated with decreased ratio of maxillary intercanine width to canine arch length. This is consistent with published associations between ankyloglossia and maxillary hypoplasia. Based on visual assessment of tongue shape and lingual frenulum in 600 individuals with Class I malocclusions in a paediatric dental practice over 18 months, Northcutt reported that when the lingual frenulum is short, the tongue will not generate enough upward pressure resulting in a narrow and underdeveloped palate.<sup>3</sup> Defabianis illustrated the relationship between restricted tongue mobility and maxillary constriction with a subject treated with lingual frenectomy, followed by spontaneous upper arch expansion without orthodontic treatment.<sup>1</sup> Guilleminault recently presented a case-control series of 150 paediatric patients with lingual frenulum that were clinically designated as short (n = 63) or normal (n = 87), and noted more “high and narrow palatal vault” among subjects in the short frenulum group.<sup>19</sup> Our investigator-blinded cross-sectional study with clinical, radiographic and dental cast measurements supports the association between restrictions to tongue mobility and maxillary hypoplasia with objective functional and anatomic measurements.

The second significant finding of this study is the association between soft palate length (PNS-P line) and tongue mobility. Restricted tongue mobility (as measured by either Kotlow free tongue or TRMR) was an independent predictor of increased soft palate length. This association remained significant when controlling for differences in the measurements of the maxilla, suggesting that the increased soft palate length was not exclusively attributable to increased draping of the soft palate tissue due to diminished tension. Prior authors have reported that soft palate length is significantly greater in OSA patients,<sup>20</sup> and

**FIGURE 6** Tongue range of motion ratio (TRMR) Grade vs Maxillary Width and Soft Palate Length by Age Cohort. Box and whisker plots are displayed outlining the 95% confidence intervals, median, interquartile ranges and outliers for the distribution of the Ratio Mx C W: AL and PNS-P measurements by age cohort



**FIGURE 7** Tongue range of motion ratio (TRMR) and Kotlow measurements by Angle Classification. There was no significant association between TRMR and Kotlow measurements vs. skeletal and dental classification in this series ( $P > .05$ )



it is well established that increased soft palate length is a prominent risk factor for upper airway collapsibility.<sup>21</sup> Soft palate length has been shown to increase progressively with ageing, weight gain and the presence of snoring, particularly among men.<sup>20,22,23</sup> We postulate that ankyloglossia may contribute to myofunctional dysfunction (in the form of open mouth breathing and/or altered swallowing pattern) that in turn promotes elongation of the soft palate.

Third, there is a lack of association between hyoid bone position (H-MN line) and ankyloglossia. Ankyloglossia is associated with a

low-tongue posture, which has been associated with an inferiorly positioned hyoid bone.<sup>24</sup> The hyoid bone is supported by soft tissue and is not spatially fixed by bony articulations. Thus, the position of the hyoid bone will vary with functional movements such as deglutition, mastication and breathing. Subjects with atypical patterns of functional movements have been previously found to have alterations in the position of the hyoid bone as compared to normal functioning controls.<sup>25</sup> We did not reproduce the association between position of the hyoid bone (H-MN line) and TRMR or Kotlow measures of tongue mobility.



Finally, we did not find an association between skeletal or dental Angle classifications with restricted tongue mobility. Two prior studies with smaller sample sizes ( $n = 30$ )<sup>2</sup> and ( $n = 150$ )<sup>14</sup> however, did report an association between ankyloglossia and skeletal Class III malocclusion.

An important limitation of the present study is the small number of patients with extremely restricted tongue mobility. There were 53 patients with Grade 3 and only 4 patients with Grade 4 TRMR in the study cohort. In addition, subjects who participated in the study had presented for orthodontic treatment and may not reflect the morphology of population-based controls. Future longitudinal studies with large sample sizes from the general population would be needed to define the impact of tongue mobility on maxillofacial development.

## 5 | CONCLUSIONS

The results of this cross-sectional study show an association between restricted tongue mobility, narrowing of the maxillary dental width and elongation of the soft palate. The present study did not find identify associations with skeletal and dental anterior-posterior relationships. Our findings suggest that variations in tongue mobility affect maxillofacial morphology, mainly in the form of a high-arched palate with transverse deficiency.

### ORCID

A. J. Yoon  <http://orcid.org/0000-0001-6807-7686>

### REFERENCES

- Defabianis P. Ankyloglossia and its influence on maxillary and mandibular development.(A seven year follow-up case report). *Funct Orthod*. 1999;17:25-33.
- Meenakshi S, Jagannathan N. Assessment of lingual frenulum lengths in skeletal malocclusion. *J Clin Diagn Res*. 2014;8:202.
- Northcutt ME. The lingual frenum. *J Clin Orthod*. 2009;43:557-565.
- Srinivasan B, Chitharanjan AB. Skeletal and dental characteristics in subjects with ankyloglossia. *Prog Orthod*. 2013;14:1-7.
- Emmanouil-Nikoloussi E, Kerameos-Foroglou C. Congenital syndromes connected with tongue malformations. *Bull Assoc Anat*. 1992;76:67-72.
- Živković Z, Golubović S. Tongue mobility in patients with cerebral palsy. *Vojnosanit Pregl*. 2012;69:488-491.
- Hertzberg J, Nakisbendi L, Needleman H, Pober B. Williams syndrome-oral presentation of 45 cases. *Pediatr Dent*. 1994;16:262-262.
- Jamilian A, Fattahi F, Kootanayi N. Ankyloglossia and tongue mobility. *Eur Arch Paediatr Dent*. 2014;15:33-35.
- Messner AH, Lalakea ML, Aby J, Macmahon J, Bair E. Ankyloglossia: incidence and associated feeding difficulties. *Arch Otolaryngol Head Neck Surg*. 2000;126:36-39.
- Pola M, Garcia MG, Martín JMG, Gallas M, Lestón JS. A study of pathology associated with short lingual frenum. *J Dent Child*. 2002;69:59-62.
- Olivi G, Signore A, Olivi M, Genovese M. Lingual frenectomy: functional evaluation and new therapeutical approach. *Eur J Paediatr Dent*. 2012;13:101-106.
- Guilleminault C, Akhtar F. Pediatric sleep-disordered breathing: new evidence on its development. *Sleep Med Rev*. 2015;24:46-56.
- Horton CE, Crawford HH, Adamson JE, Ashbell T. Tongue-tie. *Cleft Palate J*. 1969;6:8-23.
- Jang S-J, Cha B-K, Ngan P, Choi D-S, Lee S-K, Jang I. Relationship between the lingual frenulum and craniofacial morphology in adults. *Am J Orthod Dentofac Orthop*. 2011;139:e361-e367.
- Yoon A, Zaghi S, Weitzman R, et al. Toward a functional definition of ankyloglossia: validating current grading scales for lingual frenulum length and tongue mobility in 1052 subjects. *Sleep Breath*. 2017;21:767-775.
- Kotlow LA. Ankyloglossia (tongue-tie): a diagnostic and treatment quandary. *Quintessence Int*. 1999;30:259-262.
- Harris PA, Taylor R, Thielke R, Payne J, Gonzalez N, Conde JG. Research electronic data capture (REDCap)—a metadata-driven methodology and workflow process for providing translational research informatics support. *J Biomed Inform*. 2009;42:377-381.
- Rousson V, Gasser T, Seifert B. Assessing intrarater, interrater and test-retest reliability of continuous measurements. *Stat Med*. 2002;21:3431-3446.
- Guilleminault C, Huseni S, Lo L. A frequent phenotype for paediatric sleep apnoea: short lingual frenulum. *ERJ Open Res*. 2016;2:00043-2016.
- Shigeta Y, Ogawa T, Tomoko I, Clark GT, Enciso R. Soft palate length and upper airway relationship in OSA and non-OSA subjects. *Sleep Breath*. 2010;14:353-358.
- Sforza E, Bacon W, Weiss T, Thibault A, Petiau C, Krieger J. Upper airway collapsibility and cephalometric variables in patients with obstructive sleep apnea. *Am J Respir Crit Care Med*. 2000;161:347-352.
- Stauffer JL, Buick MK, Bixler EO, et al. Morphology of the uvula in obstructive sleep apnea. *Am Rev Respir Dis*. 1989;140:724.
- Malhotra A, Huang Y, Fogel R, et al. Aging influences on pharyngeal anatomy and physiology: the predisposition to pharyngeal collapse. *Am J Med*. 2006;119:72. e79.
- Chauhan A, Autar R, Pradhan KL, Yadav V. Comparison of pharyngeal airway dimension, tongue and hyoid bone position based on ANB angle. *Natl J Maxillofac Surg*. 2015;6:42.
- Carvalho EN, Nouer DF, Garbui IU, Nouer PRA. Relationship of the hyoid bone and posterior surface of the tongue for class II division 1 orthodontic patients. *RGO-Rev Gaúcha Odontol*. 2013;61:61-68.

**How to cite this article:** Yoon AJ, Zaghi S, Ha S, Law CS, Guilleminault C, Liu SY. Ankyloglossia as a risk factor for maxillary hypoplasia and soft palate elongation: A functional – morphological study. *Orthod Craniofac Res*. 2017;00:1–8. <https://doi.org/10.1111/ocr.12206>